



Avian Pox

A disease that can
affect any bird

By W.R. Davidson
& G.L. Doster

NWTF WILDLIFE BULLETIN No.24



NATIONAL WILD
TURKEY FEDERATION



Close-up, a normal, healthy wild turkey gobbler's head is bright red and wrinkled.

CHARLES J. FARMER

Avian pox is an infectious, contagious viral disease that may infect virtually any order of birds, either wild or domestic, including wild and domestic turkeys. Avian pox viruses belong to the genus Avipoxvirus and include numerous strains. The virus strains vary in virulence and the species of hosts that they infect. In much of the earlier literature the term "fowl pox" was used for poxvirus infections in turkeys, chickens and other birds; however, the broader term avian pox is now preferred because fowl poxvirus has been designated as a specific strain of avian poxvirus.

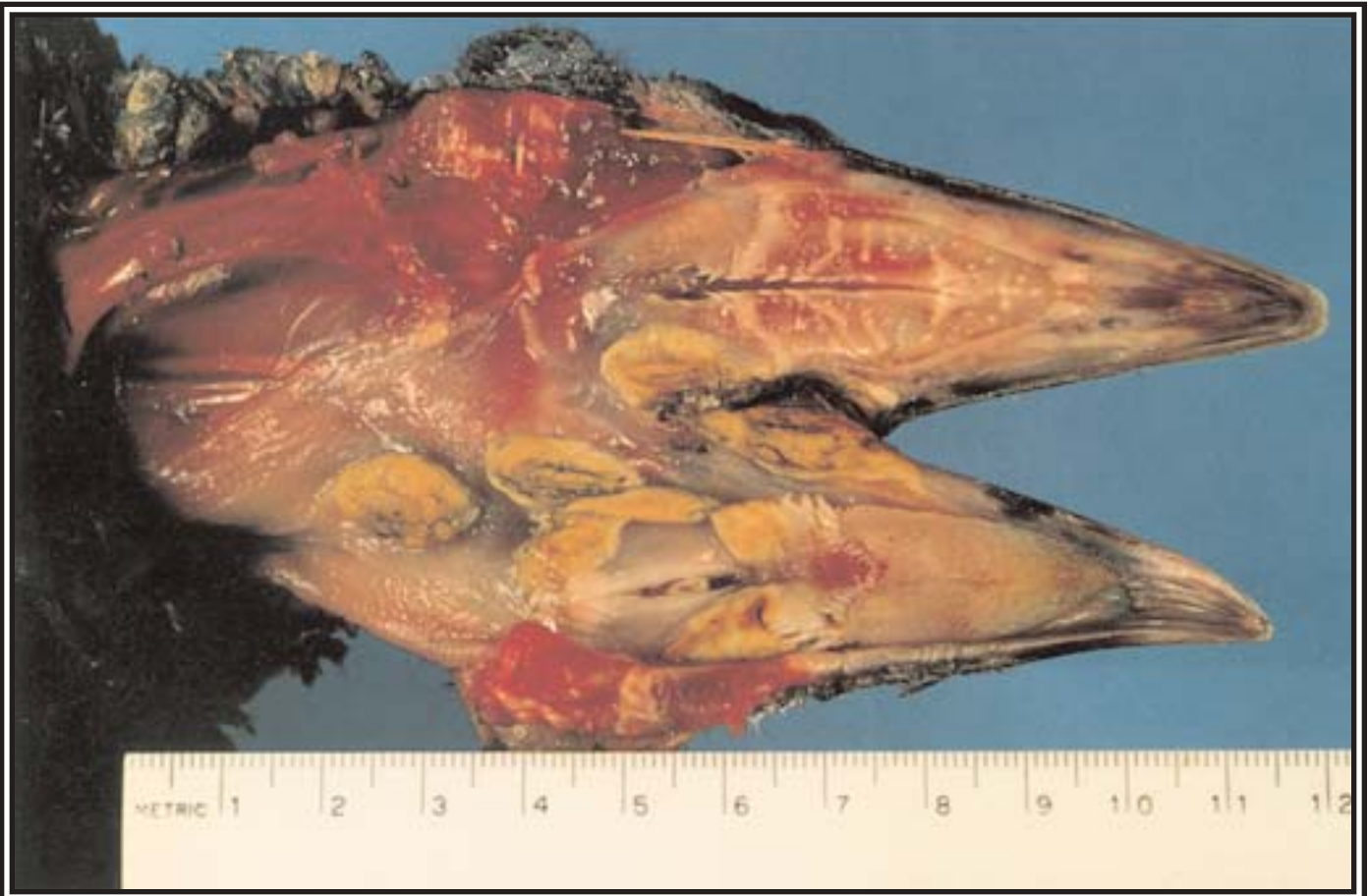

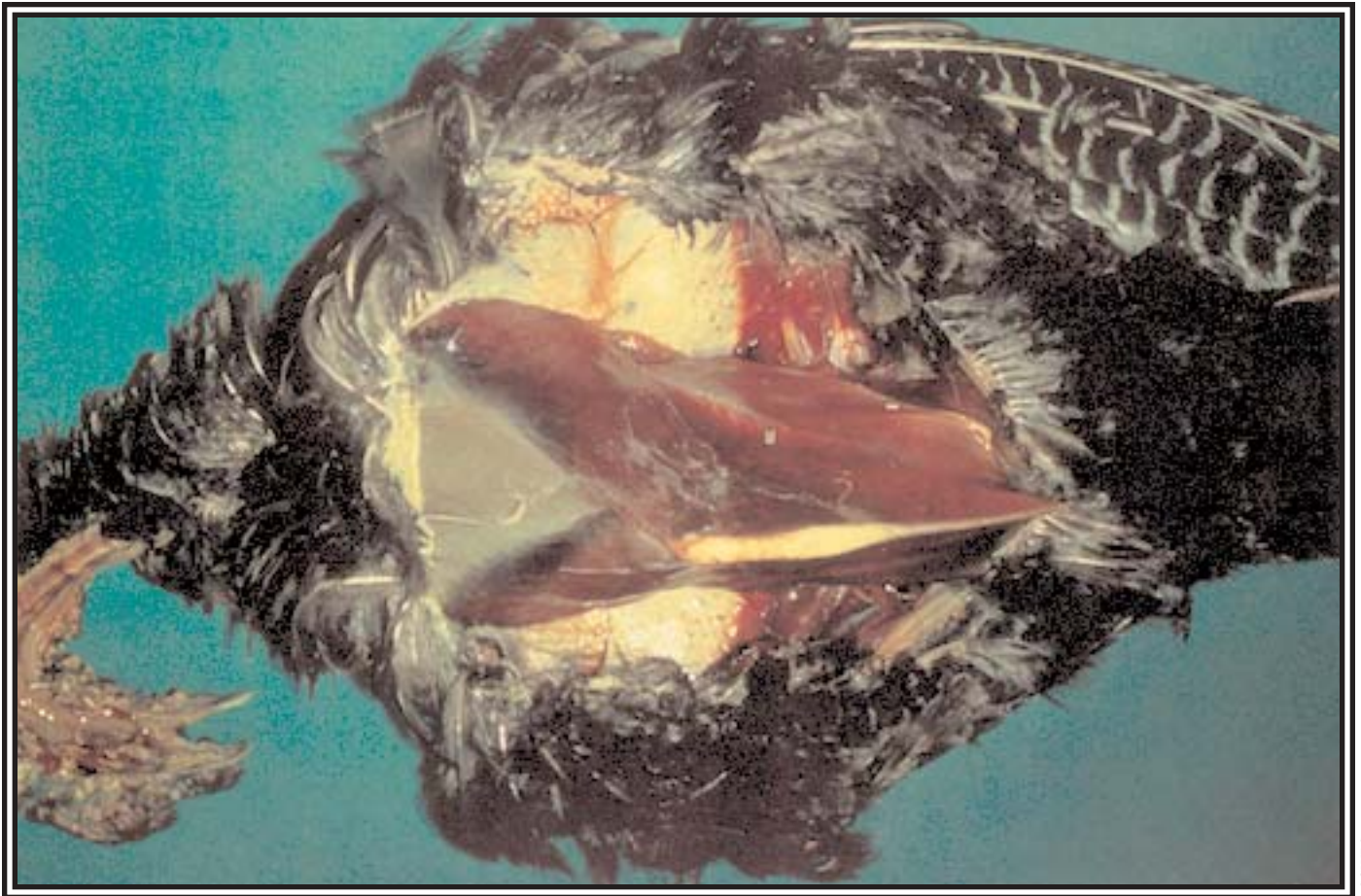
Proliferative nodular lesions on unfeathered areas of the skin are very characteristic of avian pox infections. Lesions often become abraded and scab-covered, as in this case.

The light-colored proliferative avian pox lesions depicted in the mouth of this turkey can cause debilitation or death. Wild turkeys may have either external lesions on the skin, internal lesions in the upper portions of the digestive and respiratory tracts, or both.

Avian pox is a very common viral infection that produces clinical disease among wild turkeys, especially from the eastern United States. Poxviruses infect the epithelial tissues resulting in proliferative, wart-like growths. These lesions are most frequent on unfeathered areas such as the feet, legs, eyelids, margins of the beak, and in the mouth, crop, or upper respiratory tract. Lesions often spontaneously disappear 6 to 12 weeks after initial infection.

The prognosis for infected birds depends primarily on the severity and location of lesions. Lesions in the mouth or trachea or around the eyes usually result in higher susceptibility and mortality than do lesions elsewhere on the skin. Clinical signs of avian pox may include emaciation, weakness, respiratory distress, and blindness. These signs may be totally absent in birds with only mild lesions or in birds where lesions do not impair feeding, respiration or vision. Many turkeys are infected with avian pox without the development of clinical signs. Turkeys that become debilitated due to avian pox are vulnera-





SCWDS

A necropsy photo shows severe emaciation of a wild turkey with avian pox.

ble to predation as evidenced by the ease with which they are harvested or caught by people, and consequently, many sick birds probably are removed by predators.

SAFE TO CLEAN AND EAT?

Although a wild turkey with pox lesions on its head, legs or feet may be unsightly, there are no human health risks associated with handling or eating a properly cooked infected bird.

Avian poxviruses are transmitted by a variety of means including (1) contact of the virus with abraded or damaged epithelium of the skin, eyes, upper respiratory tract, and oral cavity or (2) mechanical inoculation of the virus into epithelial tissues. Among wild turkeys, transmission by blood-feeding arthropods is probably the most important route of transmission. Mosquitoes are very important as vectors of avian poxviruses among wild turkeys in Florida, and certain species were found to be capable of

transmitting the virus for up to 4 weeks after feeding on infected turkeys. Although transmission by mosquitoes was demonstrated throughout much of the year, the majority of infections occurred during peaks in mosquito activity in late summer and fall. Annual prevalence of poxvirus infections among wild turkeys appeared to depend on precipitation patterns because of the critical relationship of rainfall to mosquito population levels.

From 1971-1994 avian pox accounted for more than 20% of the diagnoses in 266 wild turkeys found sick or dead in 10 southeastern states and submitted to the diagnostic laboratory of the Southeastern Cooperative Wildlife Disease Study at the University of Georgia in Athens. Cases of avian pox occurred in 21 of these 23 years. The geographic distribution of avian poxviruses in wild turkeys is incompletely known, although infections have been reported from Alabama, Arkansas, Florida,

Georgia, Louisiana, Mississippi, South Carolina, Tennessee, Texas, Virginia, and West Virginia. Avian pox probably occurs to some extent in much, if not all, of the range of the eastern subspecies and probably in portions of the ranges of other subspecies as well. Information on the annual prevalence of poxvirus infections is not available. However, available data suggest that the prevalence of avian pox infections in the southeastern United States is relatively high, although it undoubtedly varies greatly among years and geographic locations.

DIAGNOSIS, CONTROL AND PREVENTION:

Diagnosis of avian pox is relatively easy because the lesions usually are external and prominent; however, other infections may resemble pox and suspected pox cases should be confirmed by laboratory examinations. An easy and reliable method for confirmation is

microscopic examination of lesions that have been preserved in 10% neutral buffered formalin. Microscopic examination can reveal characteristic inclusion bodies (aggregates of virus particles) in the epithelial cells. An alternative method of confirmation is by isolation of the virus from fresh, frozen or even air-dried lesion material. The scabs that often develop over and around pox lesions may contain large amounts of virus, and virus in these scabs will remain infective without preservation.

Control of avian pox among wild turkey populations is not practical with current technology. Prevention can be accomplished in some situa-

tions by preventing virus introduction via infected birds. When trapping and translocating wild turkeys during restocking programs birds with lesions should be culled. Also, one of the reasons that pen-raised turkeys should never be used in restocking programs is because of the potential for introduction and transmission of avian pox and other diseases and parasites.

For additional information on this subject refer to *The Wild Turkey: Biology and Management*, edited by Jim Dickson. The book is available for \$59.95 from the National Wild Turkey Federation, 1-800-THE-NWTF.