

## Blackhead Disease


# Does Not Really Cause Black Heads

By W.R. Davidson  
& G.L. Doster

NWTF WILDLIFE BULLETIN No.25



NATIONAL WILD  
TURKEY FEDERATION



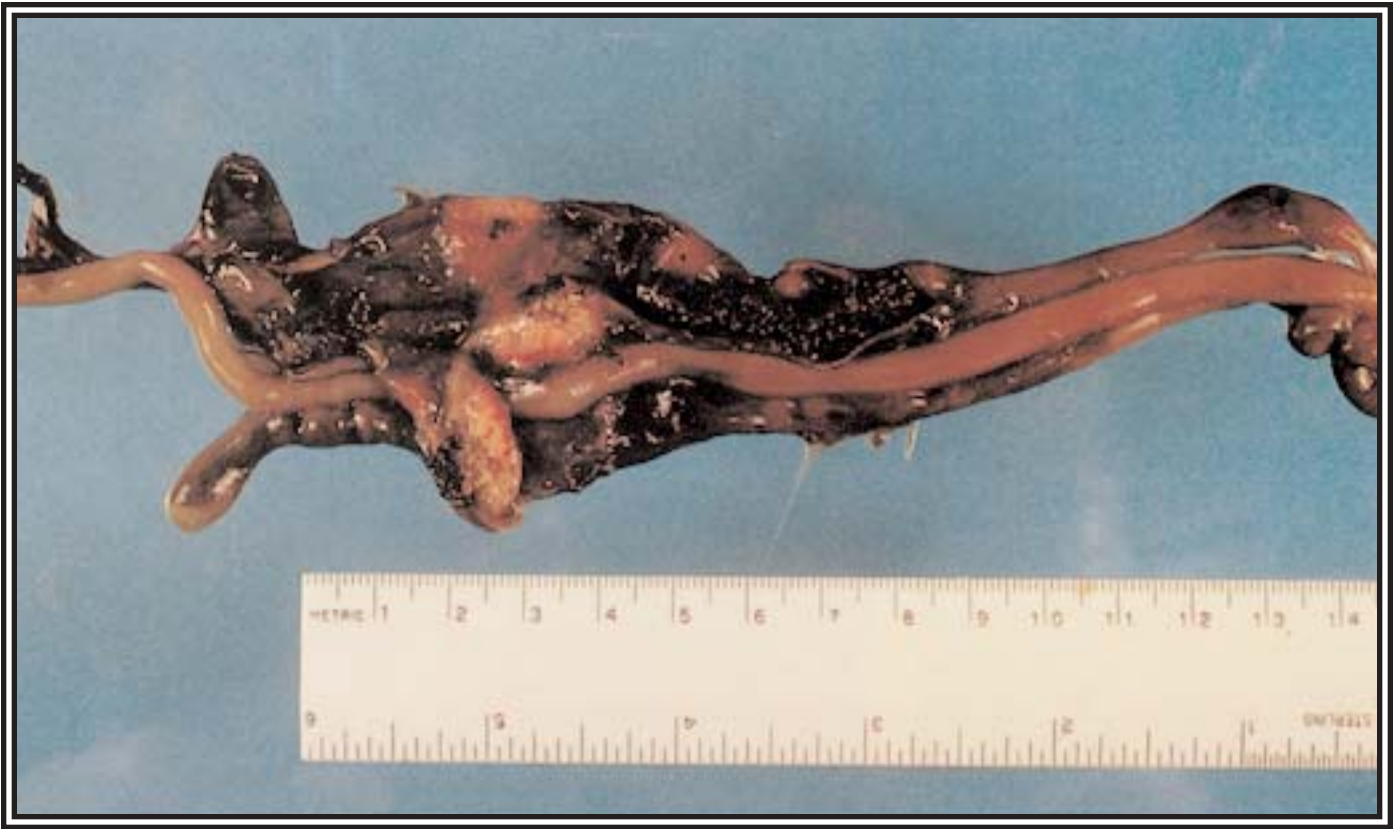
GLENN C. SMITH

*A healthy wild turkey gobbler in full strut looking for a mate.*

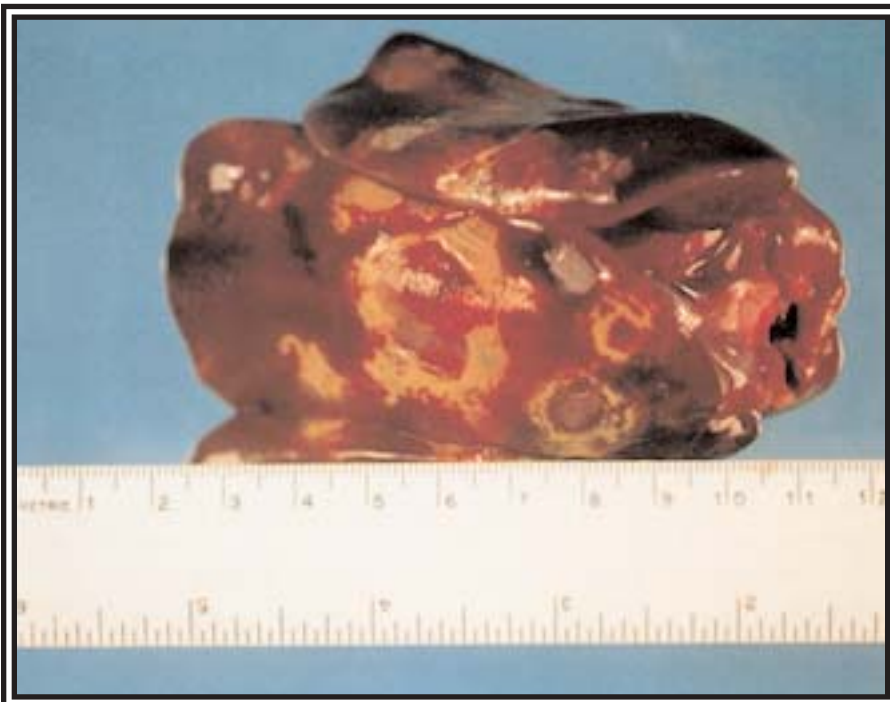
**H**istomoniasis is caused by a protozoan parasite named *Histomonas meleagridis*. Often called blackhead disease, histomoniasis primarily affects gallinaceous birds (chickens, grouse, partridge, peafowl, pheasants, quail, turkeys). The old name "blackhead disease" is a misnomer because the heads of birds infected with histomoniasis do not turn black. Despite the limited number of confirmed reports, histomoniasis is an important disease of wild turkeys.

### **SIGNS OF INFECTION:**

Clinical signs in turkeys may include sulfur-colored droppings, lethargy, drooping wings, eyes closed, head held close to the body, weakness, or emaciation. Lesions are characterized by thickening and ulceration of the lining of the ceca and by focal necrosis in the liver. The combination of swollen, inflamed ceca with yellow, cheesy cecal cores and discrete spots of necrosis in the liver is considered indicative for histomoniasis. Variations in the severity and appearance of lesions are not uncommon, however, and cecal lesions without liver involvement occur occasionally.



The cheesy core in the ceca of a turkey infected with histomoniasis.



The liver of a turkey infected with histomoniasis. Note the discolored, depressed lesions.

Histomoniasis appears frequently in the scientific, semi-technical, and popular literature in discussions of diseases of wild turkeys; however, scientifically confirmed accounts of histomoniasis in wild turkeys are relatively few. For example, it accounted for 12% of 266 sick or dead wild turkeys from 10 southeastern states that were submitted for diagnosis to the Southeastern Cooperative Wildlife Disease Study on the University of Georgia/Athens campus from 1972-1994.

Different species of galliform birds vary greatly in their susceptibility to clinical disease due to histomoniasis. The course of infection in different host species spans the entire spectrum from a total tolerance without lesions to severe disease with a very high death rate. Unfortunately, turkeys, either wild or domestic, almost always develop severe disease following infection. Chukar partridge, peafowl and ruffed grouse also are prone to severe disease. At the opposite end of the spectrum are species such as ring-necked pheasants, chickens and





DAVE MENKE/USFWS

junglefowl which rarely become sick; these species serve as carriers of the parasite for more susceptible species such as wild turkeys. Bobwhites, guinea fowl and Hungarian partridge occupy intermediate positions in which clinical disease is common, but with fewer instances of sickness or death.

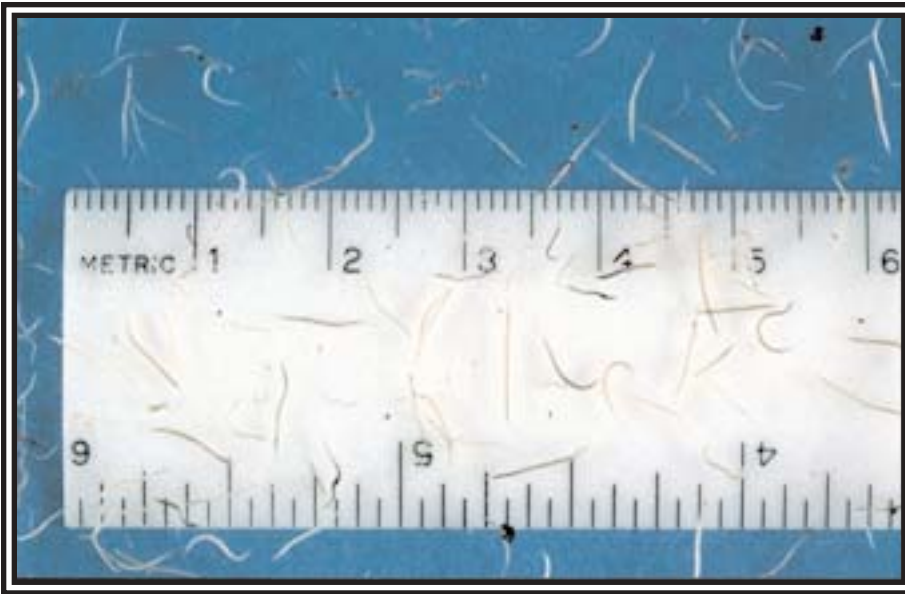
Aside from the fact that diseased avian hosts may die and be lost as a source of infection, survival of the heterakid roundworm vector in diseased ceca is extremely poor and often the worms die before the birds do. Thus, individual birds or species in which severe cecal lesions develop usually are not important sources for transmission. In contrast, hosts in which cecal lesions are absent or minimal continue to support heterakids which in turn produce large numbers of histomonad-bearing eggs.

### **WILD TURKEYS, PHEASANTS AND CHICKENS DON'T MIX:**

These epidemiologic factors are important considerations in the prevention and control of histomoniasis under field conditions. They serve as the basis of the old axiom of poultry producers "do not raise chickens and turkeys together." They also form the basis for the recommendations in place for many decades not to introduce "carrier" species such as pheasants or junglefowl into habitats occupied by wild turkeys and not to use chicken litter as fertilizer on fields or pastures frequented by wild turkeys.

Concepts regarding the disease risk posed to wild birds by the use of chicken litter as fertilizer were derived long before modern improvements in husbandry and disease control within the commercial poultry industry. Recent

*"Carrier" species, like this ring-necked pheasant should not be introduced into habitats already occupied by wild turkey populations.*



Adult *Heterakis* worms are no more than 1/2 inch long, but the females may contain several hundred eggs within which the *Histomonas* protozoa are transmitted.

research has shown that infections with both *Histomonas meleagridis* and *Heterakis gallinarum* differ greatly among commercial broilers, which are essentially free of these parasites, present virtually no histomoniasis risk when used as fertilizer on wildlife habitat. Litter from breeder birds or layers usually is contaminated with both the cecal roundworm and the protozoan that causes histomoniasis and should not be used as fertilizer on wildlife habitat. It is also recommended that wild turkeys be prevented from using the same habitat as free-ranging "yard chickens" because these chickens usually are infected with *Heterakis gallinarum* and are often carriers of histomoniasis.

The histomonads invade the lining of the ceca, producing thicken-

ing, ulceration, and hemorrhage, which are accompanied by extensive inflammation and the development of cheese cecal cores. Histomonads from the cecal lesions commonly gain entry to small veins and are carried by the blood to the liver. In the liver the histomonads continue reproducing and cause focal areas of necrosis and an intense inflammatory response. A diagnosis of histomoniasis can best be made upon examination of a fresh, refrigerated carcass. However, if it is not possible to deliver the carcass to a diagnostic laboratory within 2 or 3 days after death, a frozen carcass can be used.

The way that *Histomonas meleagridis* is transmitted from bird to bird is unusual in that it is dependent upon a parasitic round-

worm, *Heterakis gallinarum*, which also infects the ceca of many species of galliform birds. The histomonads, in addition to infecting the ceca of the bird, also infect the female heterakid worms and become incorporated within the worm's eggs. The delicate histomonads, which do not survive direct exposure to the environment, are transmitted within the protective covering of worm eggs in the droppings of infected birds. When the histomonad-bearing worm eggs are ingested by a suitable host and hatch, the histomonads are released in the ceca where they reproduce by repeated division. Birds also may acquire both heterakid worms and histomonads by consuming earthworms which can serve as transport hosts of heterakid larvae by ingesting heterakid larvae and in this capacity as transport hosts are an important means of transmission, especially under field conditions.

For additional information on this subject refer to *The Wild Turkey: Biology and Management*, edited by Jim Dickson. The book is available for \$59.95 from the National Wild Turkey Federation, 1-800-THE-NWTF.